

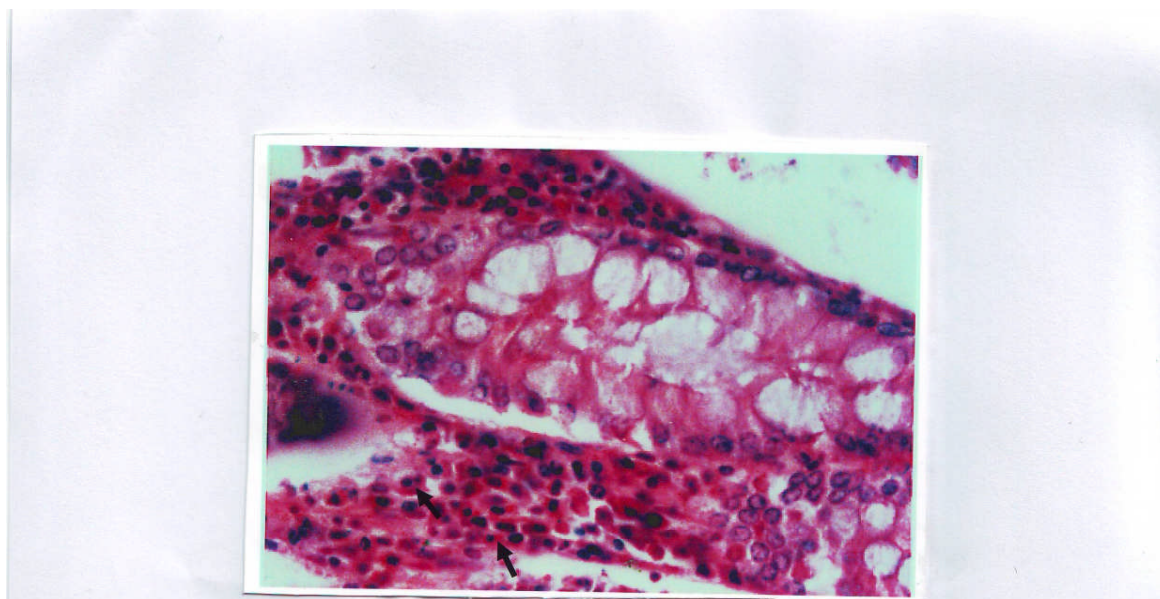Figure 1: Lymphocytes (arrow) as internal control for bcl₂ immunohistochemical staining in a section of colonic mucosal glands (alkaline phosphatase method) (red cytoplasmic staining) 400.

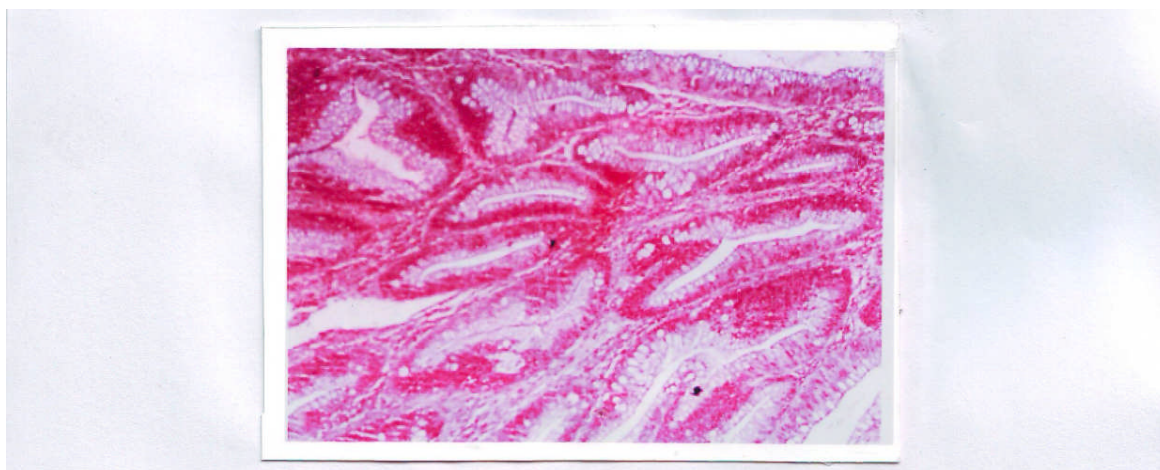


Figure 2: Normal colonic glands showing positive bcl₂ expression (alkaline phosphatase method) as red cytoplasmic stain 100.