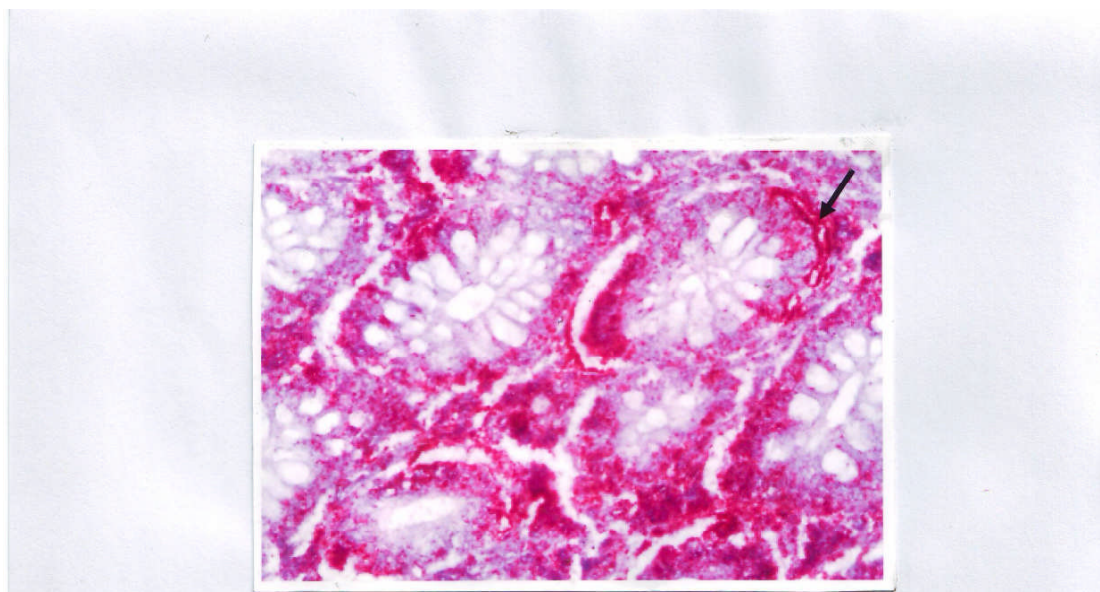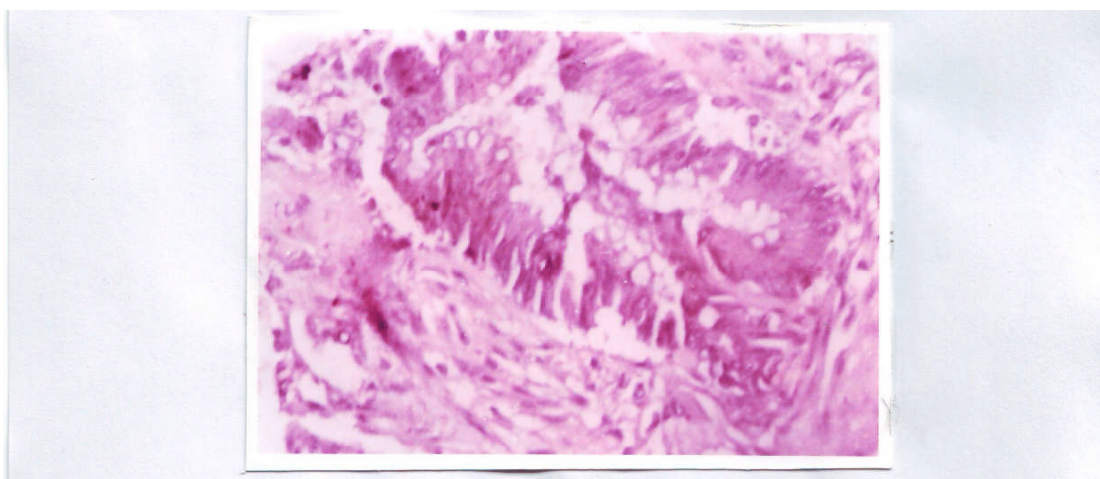


**Figure 3: well differentiated colorectal adenocarcinoma showing positive bcl<sub>2</sub> immunostaining (alkaline phosphatase method) (strong reaction) 400.**



**Figure 4: Poorly differentiated colorectal adenocarcinoma showing negative bcl<sub>2</sub> immunostaining (alkaline phosphatase method) 400.**