

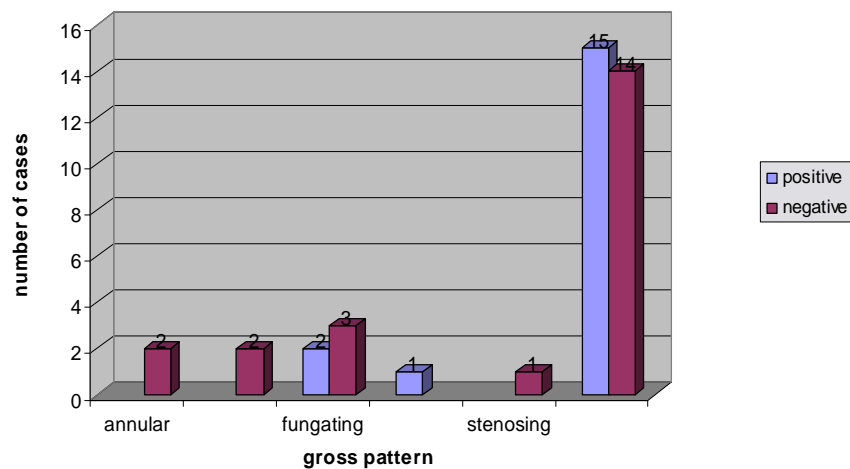Figure 2: The distribution of p53 expression according to gross pattern.

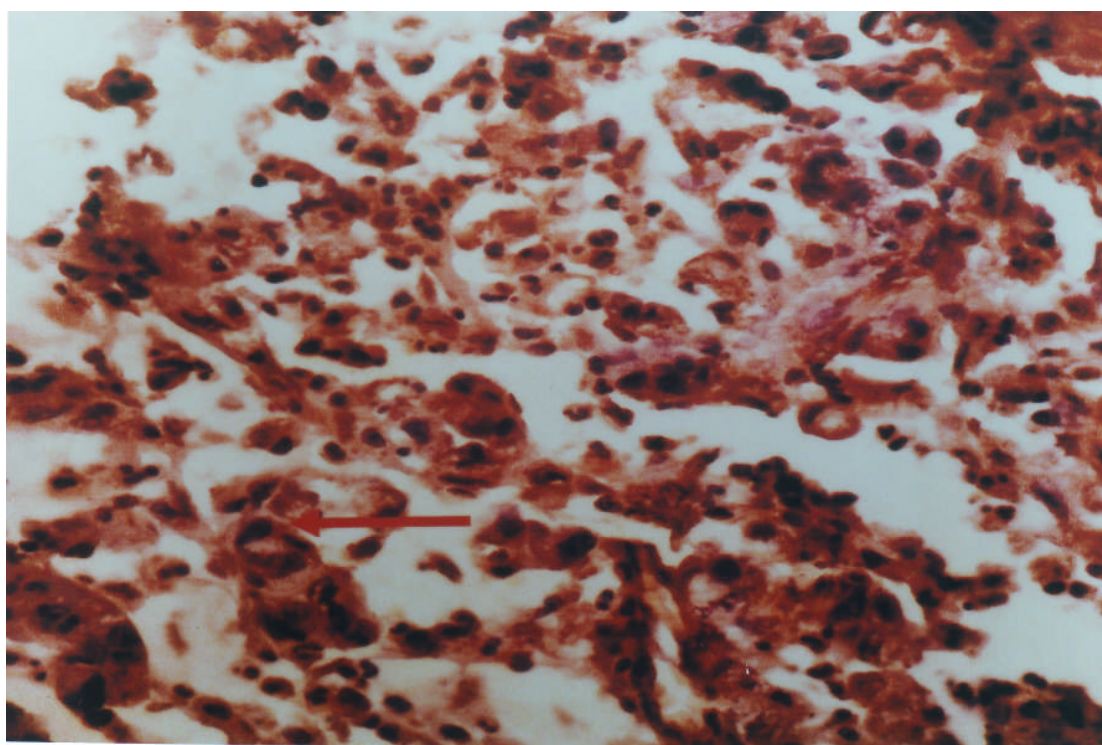


Figure 3: poorly differentiated diffuse type gastric adenocarcinoma showing positive p53 expression as brown stained nuclei (DAB method), (Arrow) at (x40).