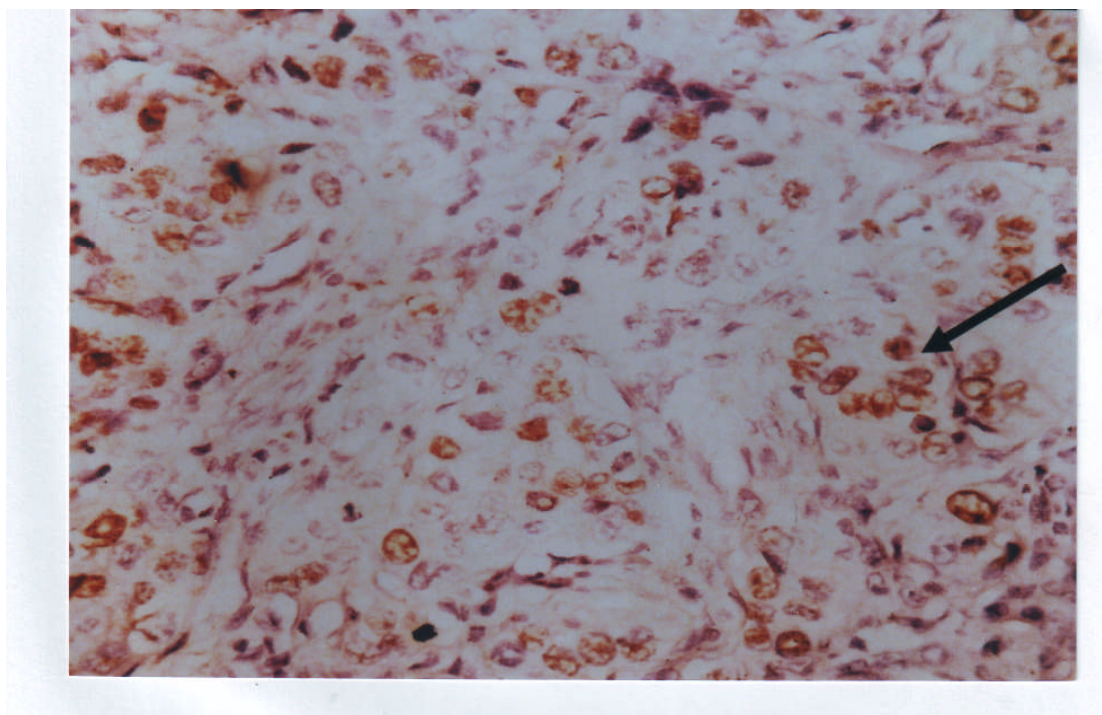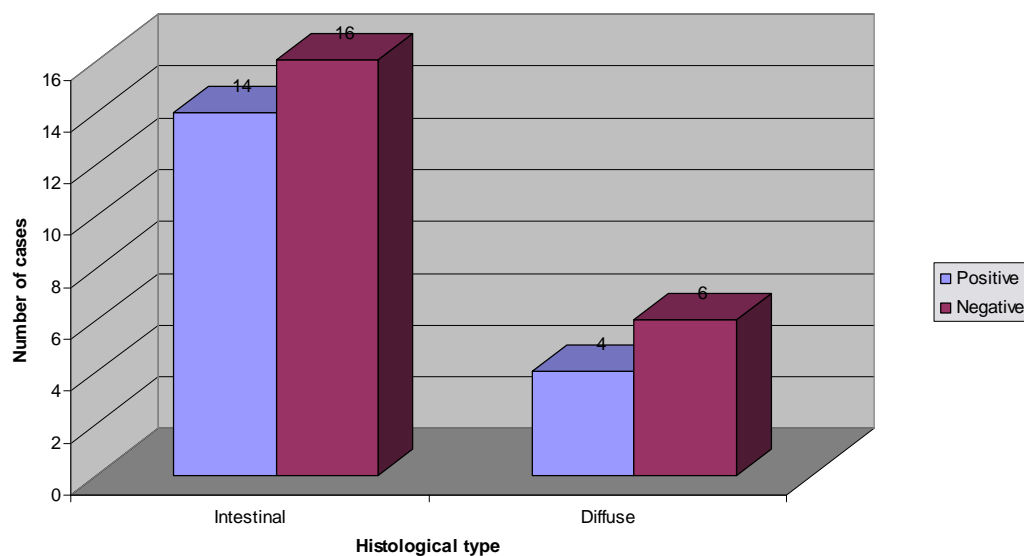


**Figure 4: intestinal type gastric adenocarcinoma showing positive p53 expression as brown stained nuclei (DAB method), (Arrow) at (x40).**



**Figure 5: The distribution of p53 expression according to histological type.**