

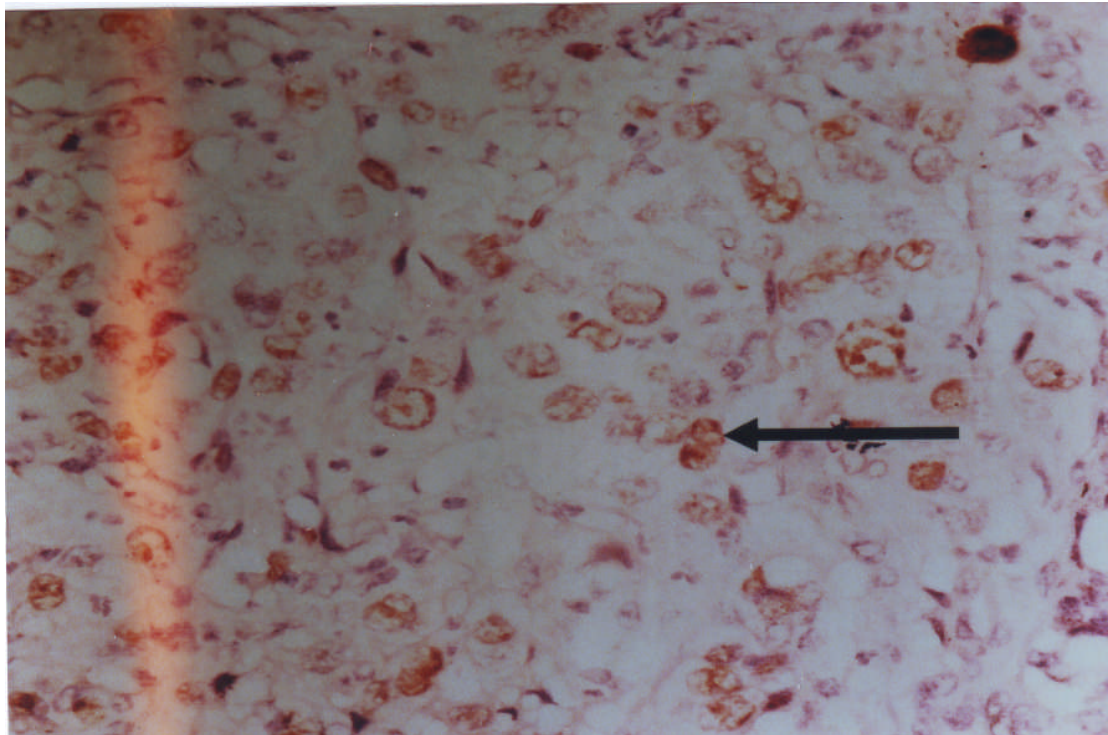Figure (8) moderately differentiated gastric adenocarcinoma showing positive p53 expression as brown stained nuclei (DAB method),(weak expression), (Arrow) at (x40).

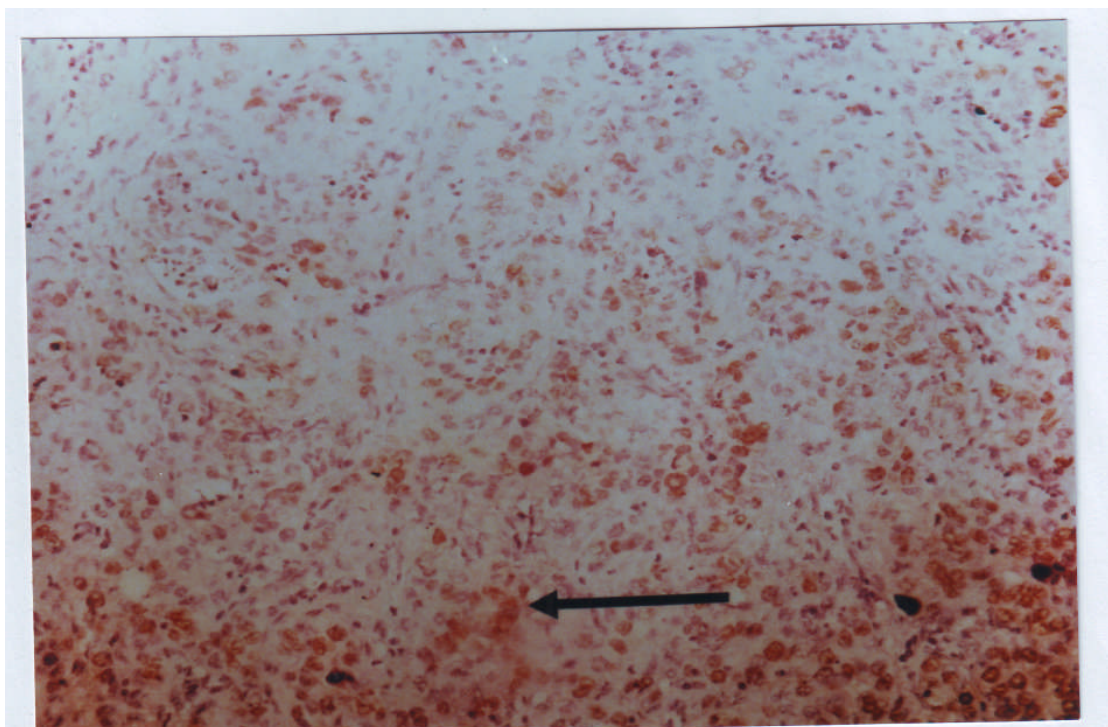


Figure 9: poorly differentiated gastric adenocarcinoma showing positive p53 expression as brown stained nuclei (DAB method),(strong expression), (Arrow) at (x10)