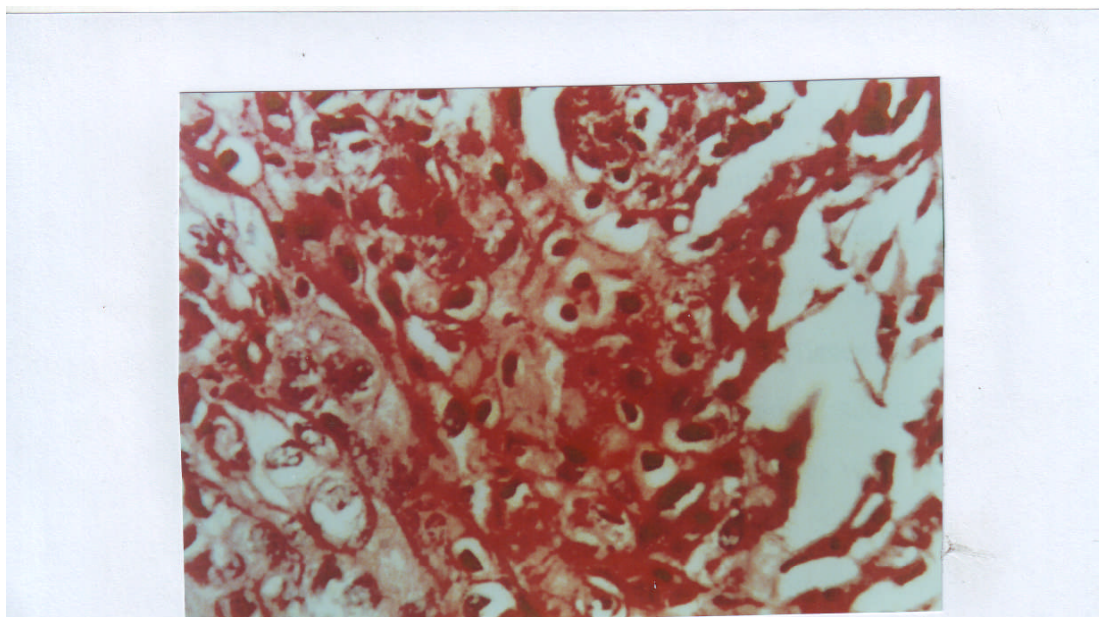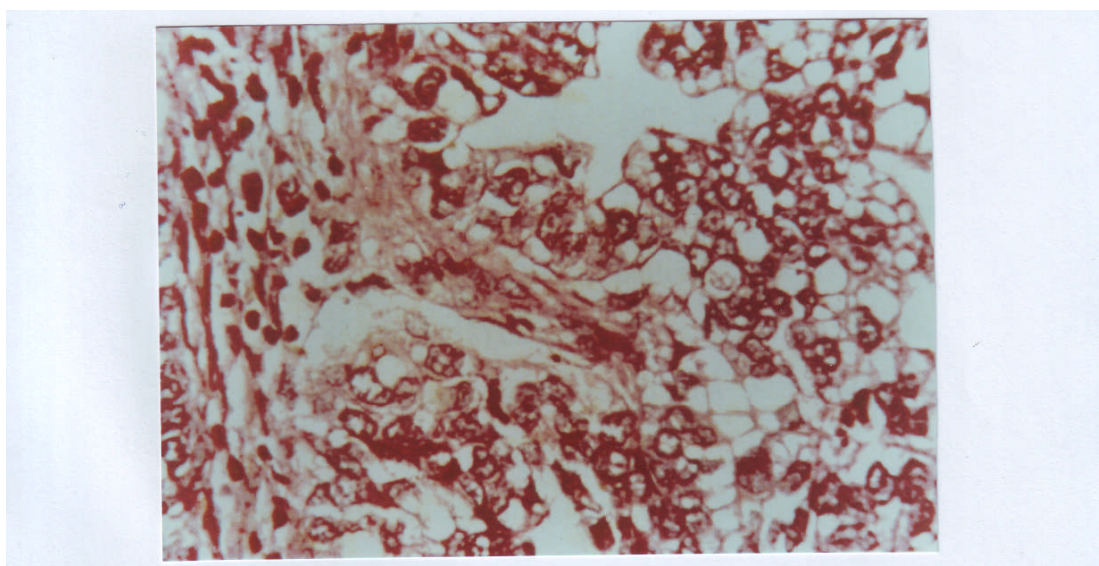


(A)



(B)

Figure 2: Histopathological section of (H&E, 400) [A] Squamous cell carcinoma of the cervix showing nests of squamous tumor cells. [B] Adenocarcinoma of the cervix showing moderately-differentiated glands.