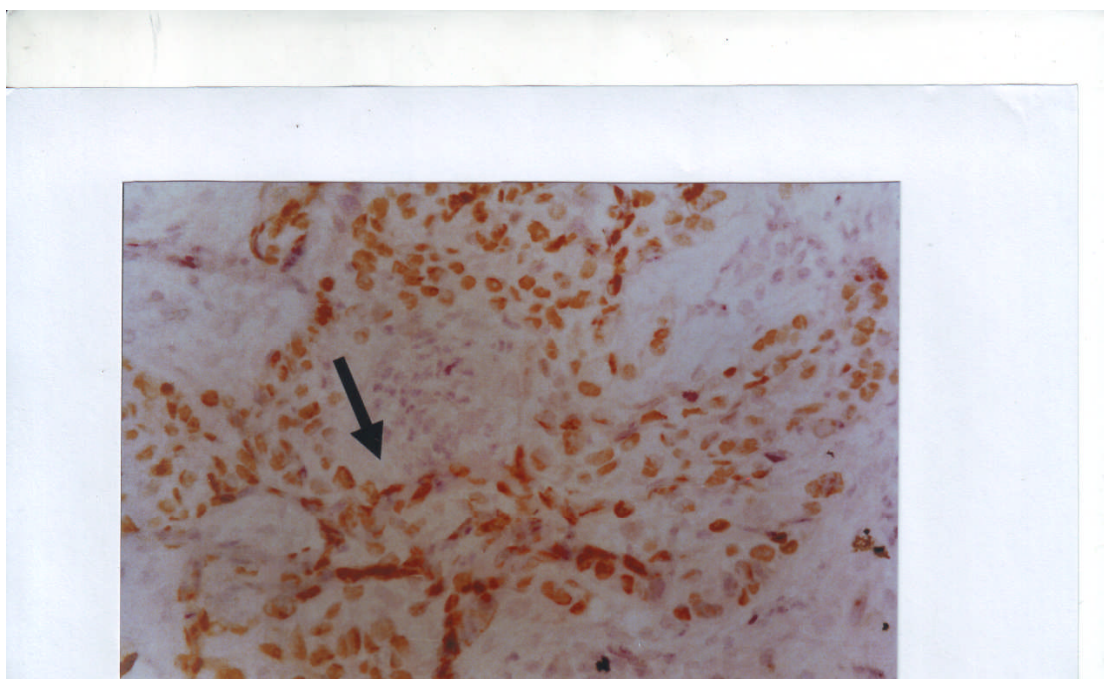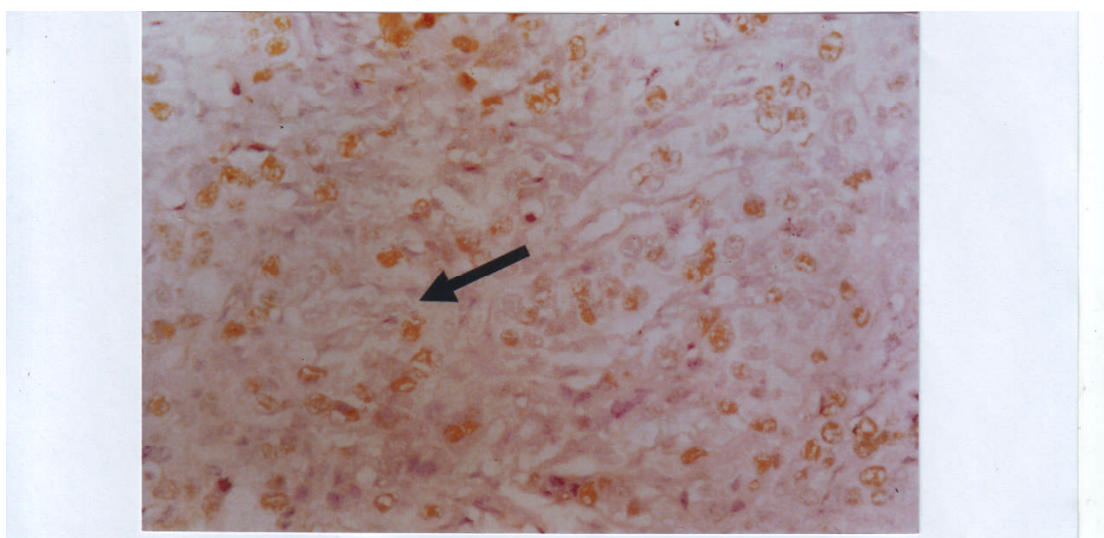


(A)



(B)

**Figure 3: Immunohistochemical staining of P53 (200) in cervical squamous cell carcinoma. Staining by DAB chromogen (brownish color) counterstained with Mayer's hematoxylin [A] Squamous cell carcinoma with a regional pattern of P53 nuclear staining (dark arrow) [B] Adenocarcinoma with a diffuse pattern of P53 nuclear staining (dark arrow)**