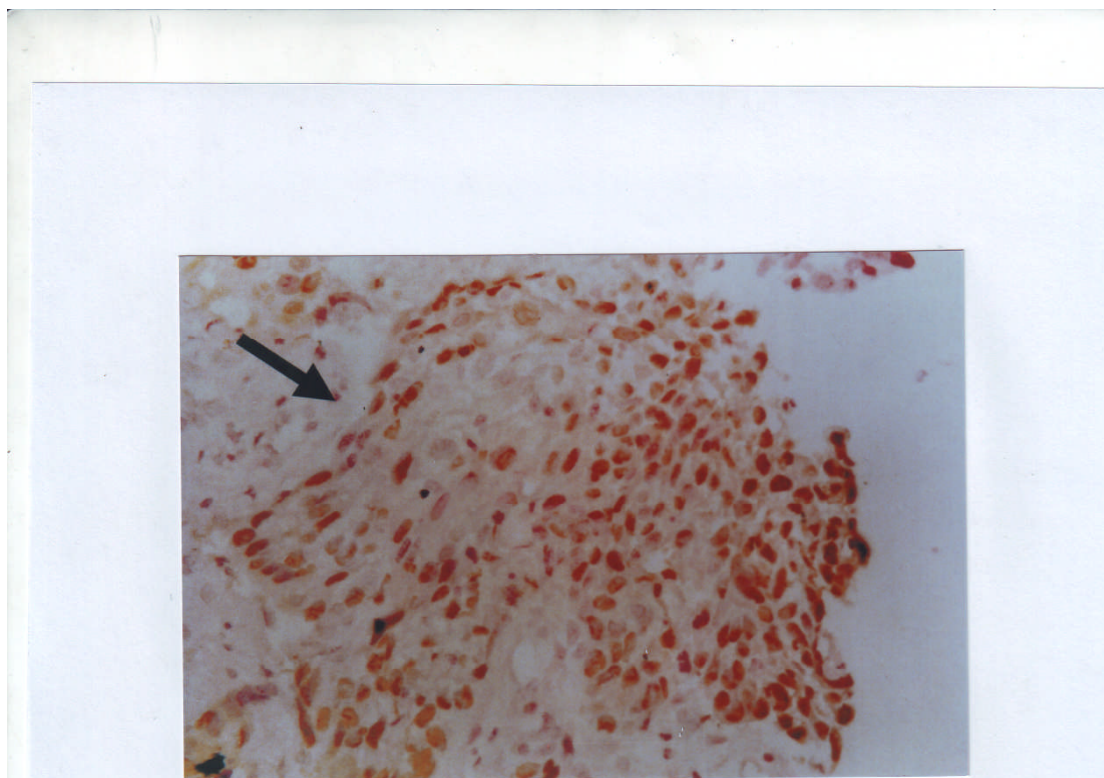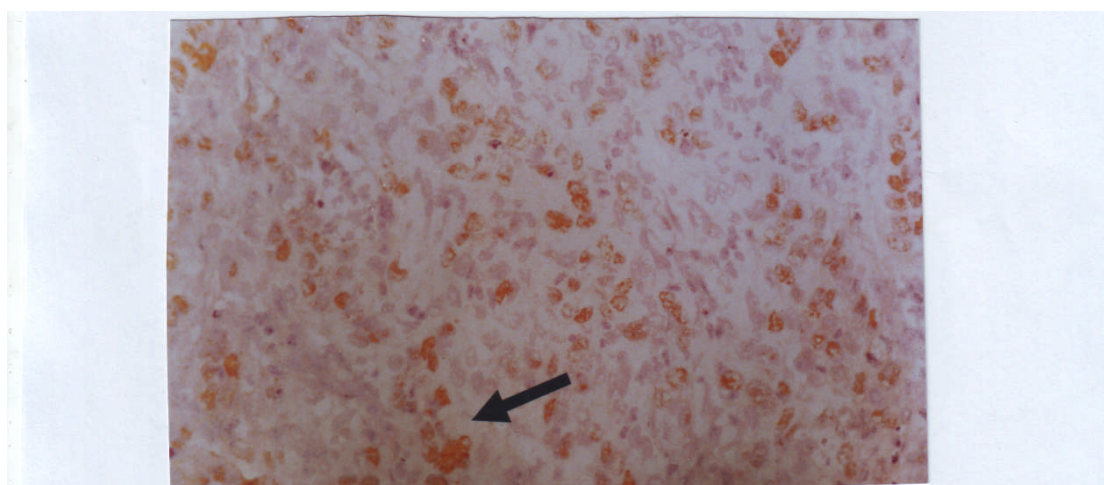


(A)



(B)

Figure 5: Immunohistochemical staining of P53 in cervical squamous cell carcinoma. Staining by DAB chromogen (brownish color) counterstained with Mayer's hematoxylin [A] Squamous cell carcinoma with strong P53 staining (>25 %-< 50%) (200) [B] Adenocarcinoma with moderate P53 staining (<25%) of the cells revealed nuclear positivity for P53 marker (dark arrow) (400)