

Green color tattoo

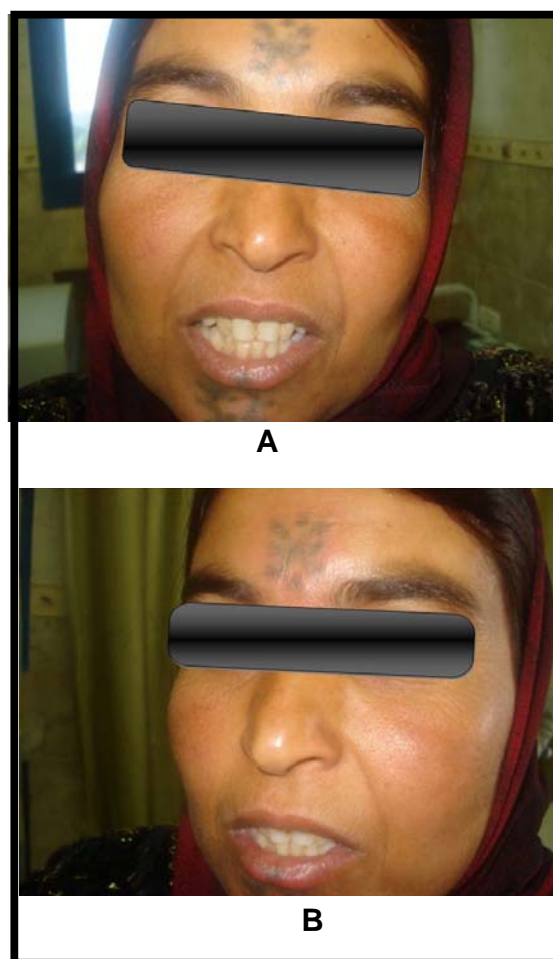


Figure 7: Green tattoo. A= 9th session. B= 10th session.

Complications

No complications have been seen like: scar, disfigurement or changing in the skin pigment, except the following transient complications have been noticed during this study (table 3 and figure 8).

1. Transient textural change was seen in (15) cases; occurred after multiple treatment sessions (figure 8, E and F). The textural change was resolved completely after 4 weeks without scarring; bepanthen ointment was used for treatment.

2. Pin-point bleeding: - occurred in (20) cases (figure 8, E and F) this due to in

direct vascular injury from photo acoustic waves generated by the laser's interaction with tattoo pigment⁽⁴⁰⁾. The pin-point bleeding was resolved within 5-7 days; it was treated by cleaning the area and topically applying antibiotic ointment and protective dressing to prevent secondary infection.

3. Systemic allergy occurred in one case only; the patient gave previous history of allergic rhinitis, the patient suffered, from joint pain, chills rhinitis, myalgia and itching after each laser treatment. Oral antihistamines and oral steroids before laser treatment are useful in this