

a wide neck urethral Diverticulum was found. An open urethroplasty Figures (2, 3) was decided with excision of the whole diverticulum and the stricture site was done with end-to-end anastomosis and closing the urethra and overlying layers.

Discussion

Urethral diverticula in males is a rare disease, very few reports in the literature about this condition, Exact incidence is unknown⁽⁴⁾.

Parker WR, Wheat J⁽⁵⁾ reported their unusual case of a 57-year-old

man with erectile dysfunction and a symptomatic urethral diverticulum after endoscopic urethrotomy for a pendulous urethral stricture. One year after surgical repair involving urethral stricture excision, end-to-end primary urethroplasty, and closure of the diverticular neck, the patient is voiding well but has persistent erectile dysfunction unresponsive to phosphodiesterase-5 inhibitors.

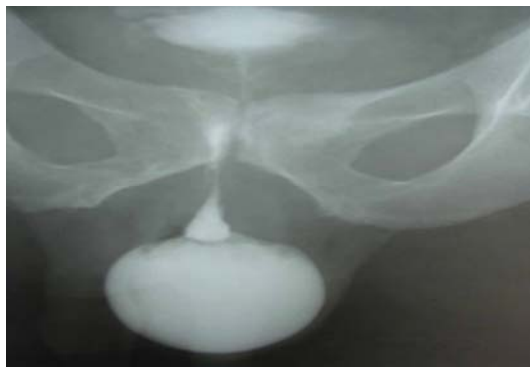

Figure 1

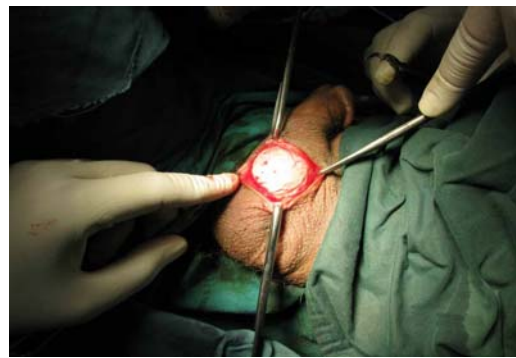

Figure 2

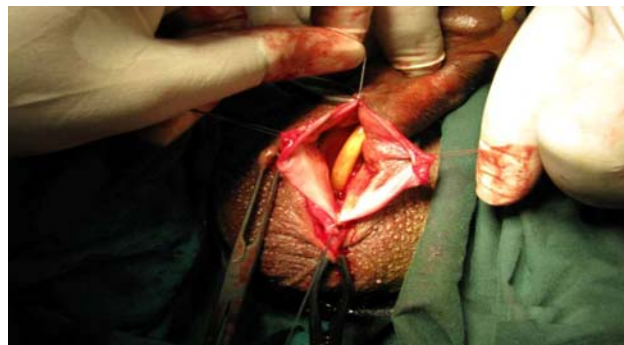


Figure 3